

# *The changes of upper airway of temporomandibular disorders patients with or without wearing stabilization splint: A cone-beam computed tomography study*

Bo Zhao<sup>1</sup>, Jinpan Liu<sup>2</sup>, Yingfeng Xia<sup>1,\*</sup>, Hua Qian<sup>1,\*</sup>

<sup>1</sup>Center of Stomatological, The Second Hospital of Shandong University, Jinan, Shandong, 250033, China

<sup>2</sup>Department of Stomatology, Ji'nan Shizhong People's Hospital, Jinan, Shandong, 250002, China

\*Corresponding author

**Keywords:** Temporomandibular disorders; Stabilization splint; Upper airway; Cone beam CT (CBCT); obstructive sleep apnea hypopnea syndrome

**Abstract:** This study analyzed the changes of upper airway in patients with temporomandibular disorders (TMD) before and after wearing stabilization splint (SS). 26 patients with TMDs in the Department of Stomatology of the second hospital of Shandong University were selected. CBCT was taken before and after wearing SS, and images were imported into mimics 20.0 software. The changes of upper respiratory related indexes before and after wearing SS were measured and analyzed. Compared with not wearing the SS before treatment, the volume of oropharyngeal Cavity, total volume, area of retroepiglottic cross-sectional areas decreased, and SN-MP increased when wearing SS after the condyle position was stable after SS treatment ( $P < 0.05$ ). The airway volume, retroepiglottic area were decreased with wearing SS. It is suggested to reduce the thickness of SS when making SS to reduce the possibility of reducing the airway volume.

## 1. Introduction

The number of cases of temporomandibular disorders (TMD) is increasing year by year<sup>[1]</sup>. For TMD patients with functional impairment, pain, and psychological discomfort, their work and life are significantly disturbed by these symptoms<sup>[2]</sup>. As there are many causes of TMD<sup>[3, 4]</sup>, treatment methods are also manifold, including wearing splints, joint surgery, psychotherapy, medication, counseling and self-care as a single treatment method or a combination<sup>[5]</sup>. Stabilization splint (SS) is one of the preferred treatments<sup>[6]</sup>, aiming to promote occlusal stability, reduce muscle tension, and adjust the position of the temporomandibular joint disc<sup>[6-8]</sup>. During treatment, the patient will wear the splint throughout the day for extended periods of time, including during nighttime sleep.

There is no research report analyzing the changes in the patient's upper airway when wearing a splint. In this study, the mimics 20.0 software was used to reconstruct and analyze the CBCT data of SS patients before and after wearing splints, and to study the impact of wearing SS on the airway.

## 2. Materials and methods

### 2.1 Research objects

A total of 26 TMD patients who visited the Department of Stomatology of the Second Hospital of Shandong University from January 2020 to December 2021 were selected, including 21 women and 5 men, with an average age of  $31.5 \pm 8.18$  years.

Inclusion criteria: ① Meet the diagnostic criteria for TMD (Diagnostic Criteria for TMD, DC/TMD); ② The patient's growth and development peak is over, and the teeth have erupted to occlusal contact; ③ The CBCT image is clear, and the range can include the upper orbital rim and the lower edge of the hyoid bone; ④ Bilateral condyles were posterior displacement in CBCT images. Exclusion criteria: ① Failed to insist on wearing splint for treatment; ② Upper respiratory tract disease when taking CBCT; ③ History of head and neck trauma, surgery, radiotherapy and chemotherapy that invades the respiratory tract; ④ History of congenital malformations of head, neck and face; ⑤ BMI > 28. This study was conducted with the approval of the Ethics Committee of our hospital, ethics approval number: KYLL-2023LW053.

### 2.2 Treatment methods

SS treatment: Silicone rubber impression was taken to make plaster cast. Occlusal recording silicone rubber was used to record the patient's centric position. Mounting articulator and adjust the parameters to make SS. The thickness of SS was about 2mm, and it was worn on the upper teeth. The time to wear SS was the whole day, follow-up visits to adjust and grind the abnormal points of occlusion, until the position of the condyle was in a stable. (Fig.1) SS was worn overnight after stabilization. The treatment process was performed by the same physician.

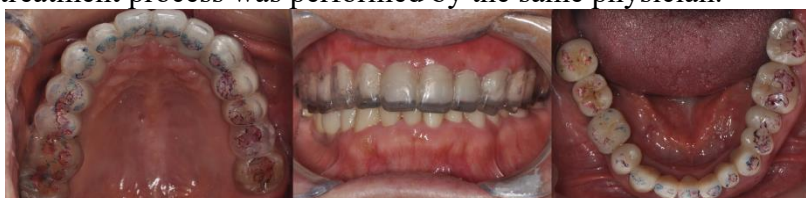

Figure 1: Intraoral and occlusal photos when wearing SS, the blue is the centric bite, and the red is the protrusive and lateral bite.

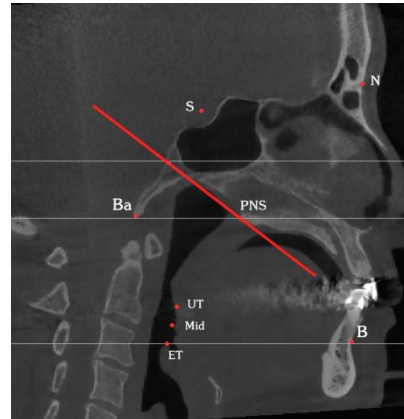
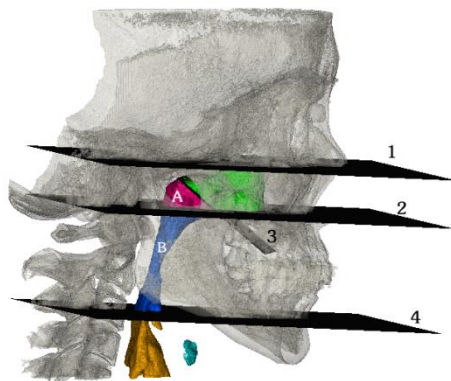
### 2.3 CBCT examination

Before the patient wore the SS and after the condylar position is stabilized (the process is about 3 to 6 months), the CBCT machine (NewTom VGi, Italy, shooting parameters: tube voltage 110KV, current 1~32mA, tube power 3.5KW, scanning time  $\leq 15$ s, focus 0.3mm) was used to scan: the patient was standing upright, the lips were naturally closed, and the maximal cusp crossing position was maintained. Light-touch bite to avoid swallowing action.

### 2.4 Measurement methods

The acquired CBCT data were imported into mimics 20.0 software. Firstly, a mask of the patient's craniomaxillofacial bone was established, the mask was reconstructed, the bilateral orbitales (O) and the right porion (P) were marked on the image, and the Frankfort horizontal plane

was drawn through these 3 points. The Frankfort plane was set as the horizontal plane in the software, the nasion (N) was marked on the reconstructed image, and the sagittal plane passing through the N is the median sagittal plane. On the midsagittal plane, the basion (Ba), sella (S), supramental (B), posterior nasal spine (PNS), top of the epiglottis (ET), and tip of the uvula (UT) were marked. The setting range of the airway mask was: -1024~394, and the airway was reconstructed in three dimensions. According to the anatomical structure of the upper airway and combined with relevant research<sup>[9-11]</sup>, the anatomical boundaries were divided. The upper boundary of the nasopharyngeal cavity: passes through the plane with the midpoint of the line connecting the Ba point and the S point and the PNS point as a straight line and perpendicular to the sagittal plane; The lower boundary of the nasopharyngeal cavity: the horizontal plane passing through the PNS; the lower boundary of the oropharyngeal cavity: the horizontal plane passing the ET. (Fig.2 and 3) Mimics 20.0 software was used to measure various indicators of the patient wearing the splint before and after treatment. (Table 1) All operations were completed by one physician within one week, measurements were taken twice, and the data obtained were averaged.



A. Nasopharyngeal cavity; B. Oropharyngeal cavity; 1. Frankfort level 2. The boundary between nasopharyngeal cavity and oropharyngeal cavity; 3. The upper boundary of nasopharyngeal cavity; 4. The lower boundary of oropharyngeal cavity.

Figure 2

Figure 3

Figure 2: Upper airway compartments segmented by dissector planes.

Figure 3: Landmarks

Table 1: Definition of indicators

	Definition
Nasopharyngeal cavity(mm <sup>3</sup> )	The cavity between the upper boundary and the lower boundary of nasopharyngeal cavity
Oropharyngeal cavity(mm <sup>3</sup> )	The cavity between the lower boundary of the nasopharyngeal cavity and the lower boundary of oropharyngeal cavity
Total(mm <sup>3</sup> )	Nasopharyngeal cavity+Oropharyngeal cavity
Retropalatal area(mm <sup>2</sup> )	The measure of area passing through UT
Retrolingual area(mm <sup>2</sup> )	The measure of area passing through the midpoint of UT and ET
Retroepiglottic area(mm <sup>2</sup> )	The measure of area passing through ET
SNB(°)	The angle of SNB
SN-MP(°)	The angle of SN-MP(MP is the tangent of the lowest part of the mandible)

## 2.5 Statistical analysis

Eligible data were analyzed by SPSS 21.0 software. Data that obeyed the normal distribution were expressed as mean  $\pm$  standard deviation ( $\bar{x} \pm s$ ); paired t test was used, and the test standard  $\alpha = 0.05$ ,  $P < 0.05$  was considered statistical significance.

## 3. Result

The intraclass consistency comparison of the two measurement data was greater than 0.85, indicating that the measurement reliability was excellent.

Compared with before treatment, the volume, total volume and retroepiglottic area of the oropharyngeal cavity were decreased when wearing SS after the condylar position was stabilized after SS treatment ( $P < 0.05$ ). The volume of nasopharyngeal cavity, retropalatal area, and retrolingual area were decreased, but there was no significant difference ( $P > 0.05$ ). The angle of SN-MP was increased ( $P < 0.05$ ). The angle of SNB was increased, but there was no significant difference ( $P > 0.05$ ). (Table 2)

Table 2: Measurement results of changes in upper airway related indicators before and after wearing SS ( $n = 26$ ,  $\bar{x} \pm s$ )

	Before wearing SS	Wearing SS	P
Nasopharyngeal cavity( $\text{mm}^3$ )	5090.36 $\pm$ 1475.52	5058.53 $\pm$ 1428.58	0.228
Oropharyngeal cavity( $\text{mm}^3$ )	12397.76 $\pm$ 3267.45	11252.66 $\pm$ 2531.63	0.003
Total( $\text{mm}^3$ )	17488.12 $\pm$ 4406.19	16311.19 $\pm$ 3504.66	0.003
Retropalatal area( $\text{mm}^2$ )	241.97 $\pm$ 99.26	228.80 $\pm$ 87.45	0.108
Retrolingual area( $\text{mm}^2$ )	226.90 $\pm$ 88.54	209.72 $\pm$ 82.45	0.071
Retroepiglottic area( $\text{mm}^2$ )	261.52 $\pm$ 89.95	230.83 $\pm$ 84.28	0.001
SNB( $^\circ$ )	77.87 $\pm$ 2.58	77.93 $\pm$ 2.35	0.666
SN-MP( $^\circ$ )	42.58 $\pm$ 4.89	43.90 $\pm$ 4.94	0.002

## 4. Discuss

Over the years, SS has become one of the most common treatment options for the treatment of TMD and has undergone a large number of effectiveness tests. It is particularly effective when joint pain and myogenic pain are the main symptoms. However, different doctors have different treatment plans and treatment periods, including wearing SS only at night or intermittently or 24 hours a day as much as possible. According to previous studies, wearing SS 24 hours a day is easier to stabilize the mandibular position, thereby achieving occlusal stability<sup>[12]</sup>. A prospective study showed<sup>[13]</sup>: The most common possible causes of TMD described by patients were parafunctional habits (clenching teeth (60%), bruxism (30%)). Either suffering from clenching teeth or bruxism, the upper and lower teeth were in contact, and the lower jaw was in a closed position, rather than the conventional resting jaw position. Therefore, it is necessary to consider the impact on the airway when wearing SS. Compared with lateral cranial X-rays, which limit research to two-dimensional analysis, CBCT provides clinicians with a three-dimensional exploration tool with more accurate imaging. Although drug-induced sleep endoscopy (DISE) can visually examine the soft tissues of the upper respiratory tract, and soft tissue imaging is clearer in magnetic resonance, the examination time and cost are higher, the examination location is limited.

After wearing SS, the position of the jaw changed, which may be one of the reasons for the change in the airway. Since the thickness of SS was about 2mm, after wearing it, the distance between the jaws passively increased, the mandible rotated clockwise, and the SN-MP increased

( $P < 0.05$ ). Dadgar-Yeganeh, A et al.<sup>[14]</sup> studied that high-angle facial profile was closely related to the history of TMD, and the minimum cross-sectional area of the airway was smaller. Celikoglu et al.<sup>[15]</sup> showed that the airway volumes of people with different vertical plane shapes were different, and the oropharyngeal volume of the low-angle group was significantly larger than that of the normal group and the high-angle group. The results of this study were consistent with the decrease in oropharyngeal volume ( $P < 0.05$ ) and the decrease in retroepiglottic airway area ( $P < 0.05$ ). With bone supporting, nasopharynx didn't change with the position of the mandible, so the volume of the nasopharyngeal cavity had no significant change ( $P > 0.05$ ).

Marco Pitarch et al.<sup>[11]</sup> found that oropharyngeal volume and total volume significantly increased in patients who wore mandibular advancement devices (MAD) to treat obstructive sleep apnea syndrome (OSAHS). The effect on nasopharyngeal volume was not statistically significant, indicating that devices acting on the mandible had limited changes in the nasopharynx. MAD is a device worn by OSAHS patients at night to pull the upper and lower teeth forward to pull the mandible forward. Generally, it has better efficacy when the mandibular protrusion reaches 50% to 75% of the maximum protrusion (about 4.8mm to 7mm)<sup>[16]</sup>. Since the SS does not have the function of MAD to fix the mandible and move it forward, there was no statistically significant change in SNB of patients before and after wearing SS ( $P > 0.05$ ). Wearing SS was less likely to affect the volume of the respiratory tract by changing the horizontal position of the mandible. A. Kerbrat et al.<sup>[17]</sup> found that MAD made by CAD/CAM significantly increased the volume of the upper airway compared with MAD made by traditional thermoforming. There was no difference in the amount of protrusion between the two. The difference lay in the MAD made by CAD/CAM with smaller occlusal vertical dimensions, so increasing the intermaxillary distance, rotating clockwise of the mandible might reduce the volume of the oropharynx.

Tongue was pushed backwards if the lingual side of the SS was too thick. Sun Fucui et al.<sup>[18]</sup> reported that narrowing of the dental arch may lead to tongue crowding, narrowing of the oropharynx, and reduction of the oropharyngeal volume and minimum cross-sectional area of the oropharynx. This is consistent with the results of this study, but due to the difference of measurement, in this study, there was no statistical difference in the reduction of retrolingual area ( $P > 0.05$ ), but there was a significant reduction in the retroepiglottic area ( $P < 0.05$ ). Therefore, when making the SS, the thickness of the occlusal surface and lingual side of the SS should be reduced as much as possible to reduce the impact on the airway while meeting the functions.

Sanders et al.<sup>[19]</sup> found that patients with high-possibility obstructive sleep apnea-hypopnea syndrome (OSAHS) had a higher incidence of TMD. With the aging of the population, the increase in obesity, and the advancement of screening and detection technologies, the prevalence of OSAHS has shown a sharp increase trend and has become a global public health problem. Sanders et al.'s study defined high likelihood as patients with a history of OSAHS or two or more OSAHS characteristics: loud snoring, daytime sleepiness, apnea, and high blood pressure. The higher incidence rate may result in a large number of patients with TMD in clinical work who have a high possibility of OSAHS. Although the American Orthodontic Association stated that a narrow airway did not necessarily cause OSAHS<sup>[20]</sup>. However, NIKOLOPOULOU M<sup>[21]</sup> found that SS might aggravate OSAHS and couldn't be used as a treatment for OSAHS. Therefore, for this group of patients, during the diagnosis and treatment process, more attention should be paid to asking whether the patients have loud snoring, daytime sleepiness, apnea or high blood pressure to avoid aggravating the patient's respiratory problems.

## 5. Conclusion

The airway volume, retroepiglottic area were decreased with wearing SS. It is suggested to

reduce the thickness of SS when making SS to reduce the possibility of reducing the airway volume.

## References

- [1] Slade, GD, et al., Painful Temporomandibular Disorder. *Journal of Dental Research*, 2016. 95(10): p. 1084-1092.
- [2] Almoznino, G., et al., Oral Health-Related Quality of Life in Patients with Temporomandibular Disorders. *Journal of Oral & Facial Pain and Headache*, 2015. 29(3): p. 231-241.
- [3] Fillingim, RB, et al., Potential Psychosocial Risk Factors for Chronic TMD: Descriptive Data and Empirically Identified Domains from the OPPERA Case-Control Study. *The Journal of Pain*, 2011. 12(11): p. T46- T60.
- [4] Slade, GD, et al., Signs and Symptoms of First-Onset TMD and Sociodemographic Predictors of Its Development: The OPPERA Prospective Cohort Study. *The Journal of Pain*, 2013. 14(12): p. T20-T32 .e3.
- [5] Slade, GD, et al., COMT Genotype and Efficacy of Propranolol for TMD Pain: A Randomized Trial. *Journal of Dental Research*, 2021. 100(2): p. 163-170.
- [6] Al-Moraissi, EA, et al., Effectiveness of occlusal splint therapy in the management of temporomandibular disorders: network meta-analysis of randomized controlled trials. *International Journal of Oral and Maxillofacial Surgery*, 2020. 49(8): p. 1042-1056.
- [7] GLAROS, AG, Z. OWAIS and L. LAUSTEN, Reduction in parafunctional activity: a potential mechanism for the effectiveness of splint therapy. *Journal of Oral Rehabilitation*, 2007. 34(2): p. 97-104.
- [8] Musa, M., et al., Quantitative and qualitative condylar changes following stabilization splint therapy in patients with temporomandibular joint disorders. *Clinical Oral Investigations*, 2023. 27(5): p. 2299-2310.
- [9] Kim, Y., et al., Three-dimensional analysis of pharyngeal airway in preadolescent children with different anteroposterior skeletal patterns. *American Journal of Orthodontics and Dentofacial Orthopedics*, 2010. 137(3): p. 306.e1- 306.e11.
- [10] Parsi, GK, et al., Volumetric changes of the upper airway following maxillary and mandibular advancement using cone beam computed tomography. *International Journal of Oral and Maxillofacial Surgery*, 2019. 48(2): p. 203-210.
- [11] Marco Pitarch, R., et al., Dimensional analysis of the upper airway in obstructive sleep apnoea syndrome patients treated with mandibular advancement device: A bi- and three-dimensional evaluation. *Journal of Oral Rehabilitation*, 2021. 48(8): p. 927-936.
- [12] Kuzmanovic Pfcifer, J., et al., Occlusal stabilization splint for patients with temporomandibular disorders: Meta-analysis of short and long term effects. *PLOS ONE*, 2017. 12(2): p. e0171296.
- [13] Ângelo, DF, et al., Prevalence of Clinical Signs and Symptoms of Temporomandibular Joint Disorders Registered in the EUROTMD Database: A Prospective Study in a Portuguese Center. *Journal of Clinical Medicine*, 2023. 12(10): p. 3553.
- [14] Dadgar-Yeganeh, A., DC Hatcher and S. Oberoi, Association between degenerative temporomandibular joint disorders, vertical facial growth, and airway dimension. *Journal of the World Federation of Orthodontists*, 2021. 10(1): p. 20-28.
- [15] Celikoglu, M., et al., Comparison of pharyngeal airway volume among different vertical skeletal patterns: A cone-beam computed tomography study. *The Angle Orthodontist*, 2014. 84(5): p. 782-787.
- [16] Yan-yan, MA, Z. Jing-jing and G. Xue-mei, Treatment outcome evaluation of different mandibular advancements using oral appliance to treat obstructive sleep apnea and hyponea syndrome: a systematic review. *Journal of Peking University (Health Sciences)*, 2017. 49(4): p. 691-698.
- [17] Kerbrat, A., et al., Clinical impact of two types of mandibular retention devices - A CAD/CAM design and a traditional design - On upper airway volume in obstructive sleep apnea patients. *Journal of Stomatology, Oral and Maxillofacial Surgery*, 2021. 122(4): p. 361-366.
- [18] Fucai, S., Y. Wanzhen and M. Yike, Effect of incisor retraction on three-dimensional morphology of upper airway and fluid dynamics in adult class I patients with bimaxillary protrusion. *Chinese Journal of Stomatology*, 2018. 53(6): p. 398-403.
- [19] Sanders, AE, et al., Sleep Apnea Symptoms and Risk of Temporomandibular Disorder. *Journal of Dental Research*, 2013. 92(7\_suppl): p. S70-S77.
- [20] Behrents, RG, et al., Obstructive sleep apnea and orthodontics: An American Association of Orthodontists White Paper. *American journal of orthodontics and dentofacial orthopedics*, 2019. 156(1): p. 13-28.e1.
- [21] Nikolopoulou, M., et al., Effects of occlusal stabilization splints on obstructive sleep apnea: a randomized controlled trial. *J Orofac Pain*, 2013. 27(3): p. 199-205.