

Progress in the application of pulsed electric field ablation in the treatment of atrial fibrillation

Yirong Zhang, Li Liu, Yongjun Li, Yifeng Tang

Department of Cardiovascular Medicine, Liupanshui People's Hospital, Liupanshui, Guizhou, 553001, China

Keywords: Pulse electric field ablation; atrial fibrillation; treatment

Abstract: As a common type of arrhythmia, atrial fibrillation has had a serious impact on the quality of life and health of patients. Traditional treatment of AF includes medical therapy and radiofrequency ablation surgery, however, these methods have some limitations, especially for patients with refractory AF. Recently, pulse electric field ablation has attracted much attention as an emerging treatment method, which has gradually become a research hotspot in the field of AF treatment with its unique mechanism and remarkable clinical effects. This paper aims to review the progress of pulsed field ablation in the treatment of AF in order to provide reference for clinical practice and future research.

1. Introduction

Pulsed electric field ablation as an emerging treatment for AF has made significant progress in recent years. This technique effectively destroys the abnormal electrophysiological tissue by applying a high-intensity, ultrashort pulsed electrical field in the heart tissue. Studies show that pulsed electric field ablation not only shows good clinical results in patients with refractory AF, but also has a lower complication rate and shorter recovery time, bringing new treatment options for patients with AF. However, despite the great potential of pulsed field ablation in clinical applications, further large-scale clinical trials and long-term follow-up studies are needed to verify its long-term efficacy and safety.

2. The prevalence and ablation of AF

Atrial fibrillation, is an arrhythmia symptom confirmed by a single 30-second lead or standard 12-lead ECG, the features presented as irregular RP intervals with no identifiable repeated P waves. If the onset of AF is self-terminated and lasts less than 7 days, this condition is called paroxysmal AF. Conversely, if AF lasts for more than 7 days and cannot self-terminate, it is defined as persistent AF^[1]. The main treatments for AF include the use of anticoagulants to prevent blood clots and stroke, and medical or other relief to reduce complications in the heart and brain blood vessels. Traditionally, antiarrhythmic drugs have been the mainstay of treatment for AF therapy, but this therapeutic approach faces challenges because of high recurrence rates and potential adverse drug reactions. As an alternative, with the advances in technology, catheter ablation has become the

preferred treatment, especially in cases of antiAF drug treatment failure. Catheter ablation therapy can significantly reduce the chance of AF recurrence compared to medication. The induction of most paroxysmal AF is associated with abnormal electrical activity originating from the pulmonary veins. Haissaguerre^[2] et al first identified focal lesions located between the atrial muscle and the pulmonary vein that produce a high frequency of electrical activity, which in turn leads to inhomogeneity of electrical conduction in the atrium and eventually triggers atrial fibrillation. Subsequent studies, such as in Chen^[3] et al, state that in up to 85% to 95% of patients with paroxysmal AF these pulmonary vein lesions are major triggers of AF, thus emphasizing the importance of pulmonary vein isolation in catheter ablation in the treatment of AF.

3. Principle of pulsed electric field ablation (PFA)

3.1 Force model of cell membranes

The structure of the membrane is essentially of the phospholipid bilayer shown in Figure 1. The structure shows a dynamic equilibrium at the mechanical level, attributed to the interaction between the spatial repulsion of the head region, the line tension of the pore edge, and the surface tension of the cell membrane itself. The repulsive force of the head region and the tension on the membrane surface together drive the expansion of the micropores in the cell membrane, while the line tension at the edge suppresses, so that the head spatial repulsion and surface tension are dynamically balanced with the tension along the edge. Under the influence of the electric field, the above balance will be broken, driving the growth of the micropore radius by the electric field force, leading to the formation of the pore within a certain scale^[4]. In the 1950s, it was shown that under the influence of the pulsed electric field (PEF), the cell membrane will form transient hydrophilic holes, which will instantly improve the permeability and conductivity of the cell membrane.

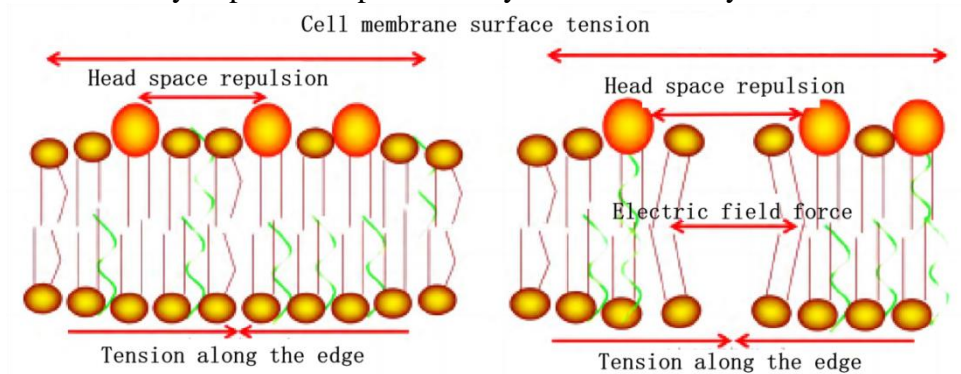


Figure 1: Power diagram of cell membrane phospholipid bilayer before and after application of the applied electric field

3.2 Reversible and irreversible electroporation

As shown in Figure 2, when a low intensity PEF (low voltage, short duration) is applied to the cell, the micropores formed on the cell membrane usually spontaneously close, and do not cause long-term damage to the cell function. The physical process of temporary hole formation in the cell membrane is called reversible electroporation (reversible electroporation, RE). On the basis of RE, enhancing parameters such as PEF intensity, duration, frequency or number of pulses may trigger the reorganization of ions inside and outside the cell membrane and destroy the physical integrity of the membrane, thus affecting the homeostasis of the molecular concentration gradient inside and outside the cell, which is crucial to the cell. While eliminating thermal effects, these processes will

eventually lead to cell death or necrosis, such a process is called irreversible electroporation (irreversible electroporation, IRE)^[5].

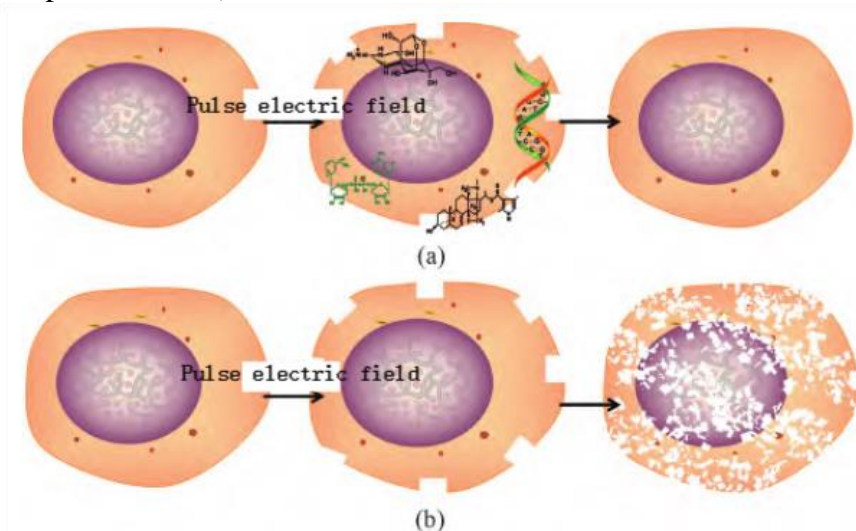


Figure 2: Schematic representation of the RE versus the IRE

4. Clinical study of PFA for atrial fibrillation

4.1 PFA for paroxysmal AF

The study by Reddy, et al^[6]Continuous pulmonary vein isolation (PVI) was demonstrated by pulse-field ablation (PFA) in two experiments. In a pulse experiment, 40 patients under general anesthesia were tested to eliminate activation of skeletal muscle using monophasic waveforms of 900 to 1000V. In another experiment, PEFCAT, all but one of the 41 patients underwent surgery while awake under general anesthesia, using a biphasic wave pattern ranging from 1800 to 2000V. After an average (6.4 ± 2.3) treatment of PFA, 100% PVI was achieved in both experiments, and no reconnection was observed after the 20-min wait time and adenosine testing. The evaluation of the invasive electrophysiology studies conducted after three months showed that the persistence of PVI was significantly increased from 18% to 100%.

On top of these findings, in 2021 by Reddy et al^[7]Published clinical results one year after PFA treatment. In the study containing 121 patients, the PFA alone yielded a 100% acute PVI success rate. At 110 patients after 93 ± 30.1 days, 84.8% of pulmonary veins maintained persistent PVI (64.5% of patients), while 96% (i. e. 84.1%) of pulmonary veins demonstrated persistent PVI when treated with optimized biphasic PFA waveform. On CT or MRI of 74 patients at approximately 99.7 ± 38.9 days after surgery, no portal stenosis was found, and the incidence of major adverse events was only 2.5%, including a cardiac tamponade, a pericardial effusion, a vascular hematoma and a transient ischemic attack^[8]. No major safety events were reported throughout the follow-up period. With the continuous optimization of the PFA waveform, the durability of the PVI is significantly improved until the new waveform achieves an unprecedented 100% success rate.

4.2 PFA for persistent atrial fibrillation

Unlike paroxysmal AF, pulmonary vein isolation (PVI) is usually not sufficient for patients with persistent AF. Additional ablation of the posterior wall of the left atrium (LAPW) has potential advantages, as supported by Bai et al and Muneretto et al: "If LAPW is ablated^[9].the ablation rate of persistent AF will also improve."The latest study by Reddy et al., further explored the use of

pulse-field ablation (PFA) in the treatment of patients with persistent atrial fibrillation. The study involved 25 patients treated for PVI, posterior wall isolation, and isolation in the tricuspid isthmus. After successful isolation of the pulmonary vein, voltage maps were recorded in the left atrium using a multipolar PFA catheter or a conventional multipolar electrode catheter. Then on the posterior wall in 24 patients by deploying a 12F strip catheter containing 4 electrodes. All electrodes underwent PFA using both wave with with voltage set at 1600 to 2000 volts with an average application time of 22 minutes. The mean posterior wall ablation time was 10 minutes, per patient at 7 different sites, and voltage mapping and lesion confirmation using a dedicated electrophysiological mapping catheter. In addition, 13 patients underwent ablation of the tricuspid isthmus through a focal catheter with an average ablation time of 9 minutes per target region, achieving an effect of acute bidirectional block in all patients. The repeated postoperative mapping procedure showed that 96%, 100%, and 100% of the lasting effects of PVI, posterior wall isolation, and valve isolation, respectively. This study validates the safety and efficacy of PFA in the treatment of patients with persistent AF.

4.3 PulseSelect Ablation System and Catheter

PulseSelect the System received FDA Breakthrough Medical Device certification in September 2018 and is conducting a prospective, multicenter, non-randomized, non-blinded global controlled clinical study (Study No. NCT04198701). Recent findings indicate that each of the 14 patients enrolled in the study achieved 100% pulmonary vein isolation (PVI)^[10]. In the study of Stewart et al., the PulseSelect system was used for pulmonary vein isolation (PFA) in six pigs with a pulse amplitude of ± 700 volts (for superior vena cava) and ± 1500 volts (for right upper pulmonary vein), indicating alternative fibrous degeneration in all ablated areas and no complications were observed. PulseSelect The catheter system has a diameter of 25 mm, and is equipped with nine electrodes of 9F, and they are arranged in a ring array. This forward-tilt 20 design is combined with a new catheter, which reduces the overlap between the electrodes and thus reduces the risk of asymptomatic cerebral embolism. Furthermore, this designed catheter has 56% more electrodes than the catheter in the vertical ring array, allowing for a more uniform contact area with the tissue.

5. Conclusion

To sum up, with the continuous progress of medical technology, the treatment method of heart disease is also constantly developing and optimized. Pulsed field ablation (PFA), as a new treatment method for atrial fibrillation, has achieved remarkable clinical results in the treatment of paroxysmal atrial fibrillation and persistent atrial fibrillation. By using pulse-field ablation techniques, we can achieve isolation of the pulmonary vein and simultaneous ablation of the posterior wall of the left atrium and the tricuspid isthmus, resulting in effective treatment of AF. This treatment has high safety and efficacy and less damage to patients. In the future, with the continuous improvement and improvement of the technology, we believe that pulse-field ablation will play a greater role in the field of atrial fibrillation treatment and bring good news to more patients.

References

- [1] Yi F, Hou W, Zhou C, et al. Radiofrequency ablation versus antiarrhythmic drug therapy for atrial fibrillation: Meta-analysis of safety and efficacy[J]. *J Cardiovasc Pharmacol*, 2019, 73(4): 241-247.
- [2] Haissaguerre M, Jais P, Shah DC, et al. Spontaneous initiation of atrial fibrillation by ectopic beats originating in the pulmonary veins [J]. *N Engl J Med*, 1998, 339 (10): 659-666.
- [3] Chen SA, Haieh MH, Tai CT, et al. Initiation of atrial fibrillation by ectopic beats originating from the pulmonary

- veins: Electrophysiological characteristics, pharmacological responses, and effects of radiofrequency ablation [J]. *Circulation*, 1999, 100(18):1879 -1886.
- [4] Reddy VY, Dukkupati SR, Neuzil P, et al. Pulsed field ablation of paroxysmal atrial fibrillation: one-year outcomes of impulse, pefcat & pefcat II [J]. *JACC Clin Electrophysiol*, 2021, 7(5): 614-627.
- [5] Verma A, Asivatham SJ, Deneke T, et al. Primer on pulsed electrical field ablation [J]. *Circ Arrhythm Electrophysiol*. 2021, 14 (9) : e10086.
- [6] Reddy VY, Neuil P, Koruth JS, et al. Pulsed field ablation for pulmonary vein isolation in atrial fibrillation [J]. *J Am Coll Cardiol*. 2019. 74(3):315-326.
- [7] Reddy VY, Dukkupati SR, Neuzil P, et al. Pulsed field ablation of paroxysmal atrial fibrillation: 1-year outcomes of IMPULSE, PEFCAT, and PEFCAT II [J]. *JACC Clin Electrophysiol*. 2021, 7(5):614-627.
- [8] Bai R, Di Biase L, Mohanty P, et al. Proven isolation of the pulmonary vein antrum with or without left atrial posterior wall isolation in patients with persistent atrial fibrillation [J]. *Heart Rhythm*. 2016. 13(1):132-140.
- [9] Muneretto C, Bisleri G, Rosati F, et al. European prospective multicentre study of hybrid thoracoscopic and transcatheter ablation of persistent atrial fibrillation: the HISTORIC-AF trial [J]. *Eur J Cardiothorac Surg*. 2017. 52(4): 740-745.
- [10] Reddy VY, Anie A, Koruth J, et al. Pulsed field ablation in patients with persistent atrial fibrillation [J]. *J Am Coll Cardiol*. 2020. 76(9):1068-1080.