

# *Case Report: A Case Report and Literature Review on Surgical Treatment of Multiple Gouty Stones throughout the Body*

Pan Zhou<sup>1,a</sup>, Zhimin Nie<sup>1,b</sup>, Xingwen Meng<sup>1,c</sup>, Wanping Lv<sup>1,d</sup>, Yu Lei<sup>1,e,\*</sup>

<sup>1</sup>Chengdu Rheumatology Hospital, Chengdu, Sichuan, China

<sup>a</sup>464834845@qq.com, <sup>b</sup>1025995453@qq.com, <sup>c</sup>mxw18030718376@163.com,

<sup>d</sup>1345999563@qq.com, <sup>e</sup>backerly@163.com

\*Corresponding author

**Keywords:** Gouty arthritis; gout stones; gout stone removal surgery

**Abstract:** The formation of gout stone can affect the appearance of local skin, and in severe cases, it can lead to skin breakdown, bone destruction, joint deformity, or even fracture, which aggravates the physical and mental burden of patients and has a severe impact on their daily life and work. This paper analyzes the surgical treatment of a case of generalized multiple gout stones in our hospital; after three surgeries, the gout stones were excised with a total of 985.6 g. The patient's uric acid was reduced to the normal range after the surgery, the skin at the ulcerated area was repaired, the joint function and appearance were improved obviously, and the patient regained the ability of self-care.

## 1. Introduction

Gout is an inflammatory disease caused by a long-term increase in blood uric acid and extensive deposition of urate crystals. Gout stone is the characteristic manifestation of gout when the blood uric acid progressively rises over the solubility of urate crystals gradually deposited to form gout stone[1]; gout stone can involve multiple organs and parts of the body in the local formation of specific granulomas[2]. Gout stone is prevalent in the joints of the limbs, leading to localized bone destruction and deformation, damage to the joints around the nerves, tendons, ligaments, and other parts of the joints, and severe disability can be caused. As the gout stone increases in size, the skin on the surface becomes thin and breaks down, and the broken place remains unhealed for a long time, which can cause local or systemic infection. Surgical treatment can assist the drugs in removing the uric acid crystallization stock in the body faster and more effectively, which is conducive to the blood uric acid standard and shorten the course of treatment; it can better protect the bone and joints, eliminate the tendons, nerves, blood vessels jammed, and improve the function of the joints; it can reduce the burden on the kidneys, and protect the renal function; it can reduce the risk of the occurrence of the development of cardio-cerebral and cerebral vascular disease; it can also reduce and remove the acute attacks of gout; and at the same time it can be very straightforward to Improve the appearance of joints, easy to wear clothes and shoes, and facilitate patients to return to society faster and better. There is no unified surgical indication, timing, and

operation point for treating gouty arthritis. In addition, due to the characteristics of the disease itself, coupled with the division of existing medical institutions, the surgical treatment of gouty arthritis gout stone has also become one of the clinical difficulties.

## 2. Case Presentations

The patient is a 54-year-old farmer who was admitted to the hospital on March 6, 2023, with "recurrent polyarticular pain for 15 years".

Laboratory and auxiliary examinations: gout stones of different sizes were found on both hands, wrists, elbows, knees, ankles, feet, subcutaneous limbs, and buttocks (Figure 1), with limited movement of multiple joints; the surface of the gout stones on the left knee, the right ankle, and the right foot were slightly ulcerated with no exudation. Bone friction sounds were cheerful in both knees, with limited flexion and extension, and the "4-word test" was positive on the right side. Musculoskeletal ultrasonography showed urate deposition in the joints of both elbows, wrists, knees, ankles, and feet, with some cartilage showing the "double-track sign," synovial membrane hyperplasia, effusion, bone erosion, and some tendon gouty tendonitis with gouty stone formation; the radial nerve of both elbows and the ulnar nerve of the left side was slightly compressed; the median nerve of both wrists was somewhat compressed; the peroneal nerve of both knees was slightly compressed; Left ankle posterior tibial nerve compression; left knee popliteal fossa cyst; bilateral knee joint medial gap narrowing, meniscus bulging, uneven thickness of femoral trolley softness (Figure 2).DR films showed gouty stone formation in the left shoulder, both elbows, wrists, hands, knees, ankles, and feet, with bone destruction in some joints; degenerative changes in the joints of both knees; and necrosis of the femoral head in the right hip joint. Microcirculation examination: moderate abnormality. Blood pressure 160/105 mmHg, uric acid 570.5  $\mu\text{mol/L}$ .

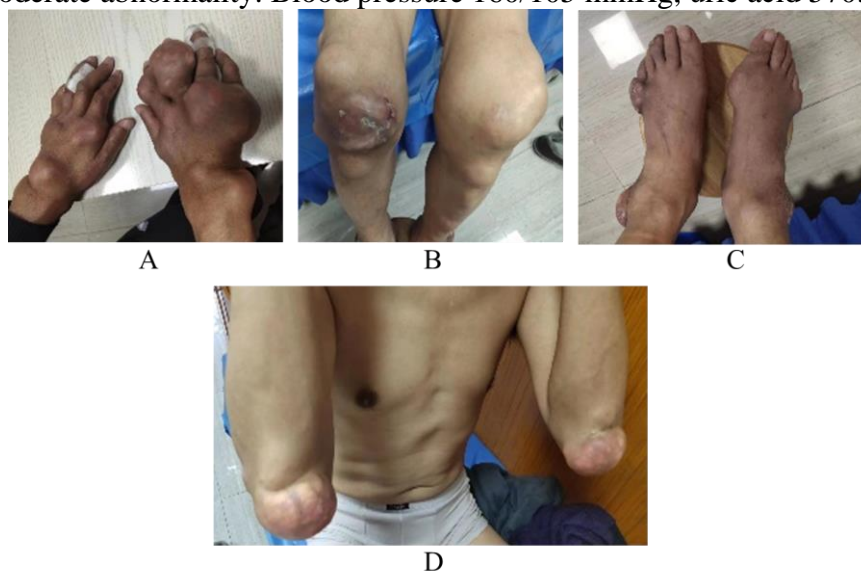


Figure 1: Demonstration of patient's polyarticular gouty stone. A-D: Gout stones of varying sizes are seen on both hands, both elbows, both knees, both ankles, both feet, and the subcutaneous parts of the extremities, and the surface of the gout stones on the knees, the right ankle, and the right foot is little broken without exudation.

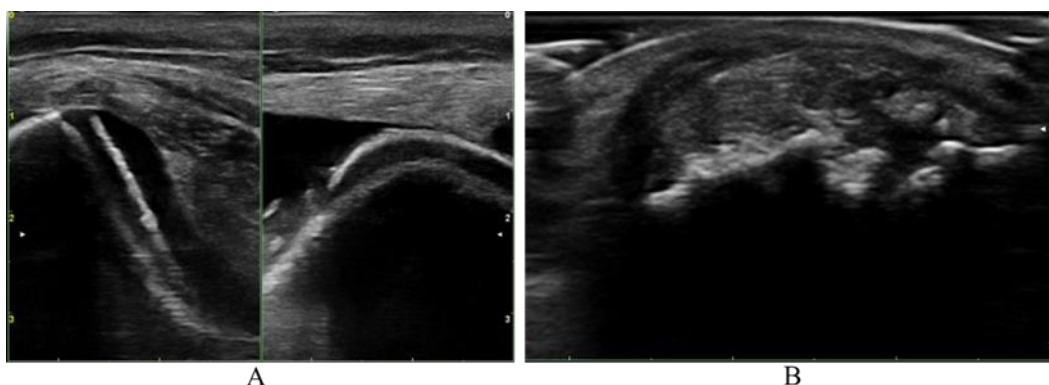


Figure 2: Musculoskeletal ultrasound results. A-B: Narrowing of the medial knee joint space in both knees, meniscal bulge, and uneven thickness of the soft femoral trochanter.

Admission diagnosis: (1) gouty arthritis, gouty stone stage; (2) osteoarthritis of both knees. After admission, the patient was treated with (1) triple oxygen autologous blood therapy to improve blood and oxygen supply to tissues and organs, improve microcirculation, and improve immunity; (2) febuxostat 10mg.qd, colchicine 0.5mg.qd; (3) traditional Chinese medicine internal and external treatments to improve the constitution, support the positive and eliminate the evil, and regulate the internal organs' function; (4) surgical excision of gout stone. In this case, the patient has a long course of disease, a massive volume of multiple gout stones in the whole body, concomitant diseases, decreased emergency compensatory capacity, and higher surgical risk. The first stage of gout stone surgery was performed in stages to minimize the time of a single operation, and the gout stone removal was conducted in the order of right upper limb, then lower limb, and left upper limb. On March 8, under proper brachial plexus anesthesia, gout stone removal surgery was performed on the right hand, the right wrist, and the right elbow, and the joints and the surrounding tissues were loosened, sculpted, and repaired while the gout stone was removed, and the appearance of the joints was significantly improved after the operation; the nerves and tendons of the wrist were relieved of compression, and the numbness of the fingers was relieved of compression, and the numbness of the fingers was reduced. After the operation, the appearance of the joints improved significantly; the nerves and tendons of the wrist joints were relieved from the pressure, the numbness of the fingers disappeared, and the joints, tendons, ligaments, nerves, and major blood vessels were intact and preserved. On March 11, the subcutaneous excision of the gout stones of the knees, ankles, feet, Achilles tendons of the bilateral buttocks, and the right lower limb were carried out under complex anesthesia: the gout stone in the left knee joint broke down, and led to the skin on the surface of the gout stone became thin, poor elasticity, scarring, and degeneration of tissues, and the healing of wounds was difficult, so a straight incision was selected for the incision design. When the surgical incision is selected, linear incision, S-type incision, and Z-type incision are favorable for wound decompensation and coverage.

During the operation, the undesirable skin tissues were removed as much as possible, and at the same time, the damage to the subcutaneous vascular network was reduced, and the interrupted decompression suture was closed (Figure 3); attention was paid to the gentle technique, and careful separation and those with erosion and fusion were not thoroughly cleaned up, and were left to be gradually dissolved in the later stage of the operation by internal medicine treatment. Some tendons and ligaments with severe erosion were performed in phase1 of the process to be repaired or reconstructed. The suitable knee gout stone was wrapped and adhered to by the joint capsule and synovial membrane connected with the joint cavity. The surgical excision of the gout stone joint capsule and the synovial membrane was large in scale, which made the surgical separation and stripping difficult, and it was easy to injure tendons, nerves, and blood vessels. It was difficult to

close the joint cavity. The autologous tissues were transplanted during the operation to repair and seal the standard hole and the synovial bursa to maximize the possibility of improving joint function after the procedure. Left hand, left wrist, left elbow, gout stone excision, etc. Under left brachial plexus anesthesia on March 27. The total amount of gout stones removed during the three operations was 985.6 g. The patient was discharged from the hospital on April 2 and continued to recuperate at home. The first stage of treatment was completed, with the wounds healed in stage I (Figure 4). Comparison of ADL before and after treatment: preoperative: 80 points, grade 1; one month after surgery: 100 points, grade 0; she could take care of herself daily.

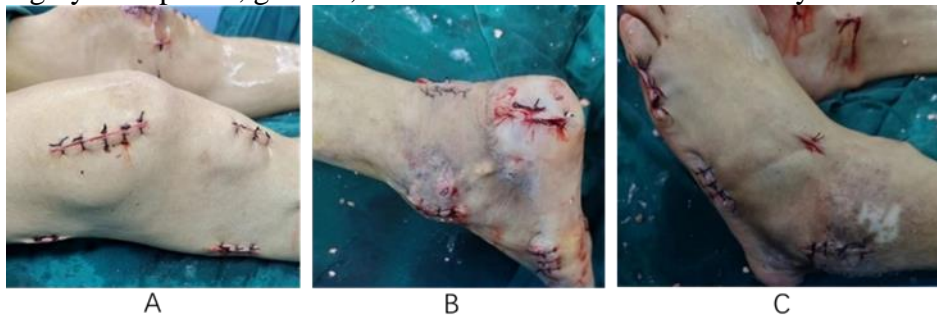

Figure 3: Gouty stone excision of both lower extremities. A-C: Wound closure of straight incisions, S-incisions, and Z-incisions for excision of gout stones in both lower extremities.

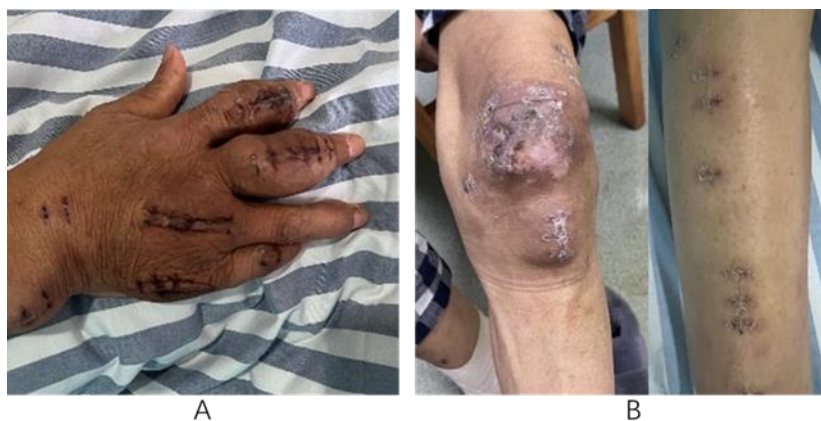

Figure 4: Wound healing in phase I. A: Wound healing after excision of gout stones in the left hand; B: Wound healing after excision of gout stones in the right knee and left arm.

### 3. Discussion

Gout is a chronic arthritis due to disturbances in purine metabolism and decreased excretion of uric acid[3]. Monosodium urate crystals deposited in and around the joints can trigger an intense inflammatory response, causing gouty arthritis attacks. Gout stones form when urate crystals are deposited in body tissues, causing chronic inflammation and proliferation of fibrous tissue. They are often deposited in the synovium, cartilage, bone, tendons, ligaments, subcutaneous fat, and skin. It occurs mainly in the first metatarsophalangeal joint of the thumb, fingers, wrists, elbows, knee joints, and other joints, resulting in severe pain, dysfunction, or even disability[4,5]. A foreign study comparing the medication adherence of patients with various chronic diseases found that the observation of gout patients was only 36%, and the incidence of gout stones in gout patients was about 12%~35%[6]. Gout stones involving joints may cause gouge-like changes in joint surfaces, and pathological fractures may occur in severe cases, which cannot be reversed or corrected by

simple drug treatment. Surgery is one of the most effective treatments for gouty arthritis, especially in the gouty stone stage. Surgery can quickly and effectively improve joint function and self-care ability and has an irreplaceable role in blocking or reversing the localized pathological process of joints. There has been no uniformity about the indications for gout stone surgery, and the indications for gout stone surgery that we summarized are: (1) large size of gout stone, with a diameter larger than 2 cm or more; (2) gout stone destroying joint bone and affecting joint function; (3) gout stone compressing tendons, nerves, and blood vessels, affecting distal limb blood flow and function, and leading to numbness, etc.; and (4) thinning of the skin on the surface of the gout stone, ulceration, infection etc; (5) repeated acute inflammation at the gout stone site, leading to severe pain and affecting function; (6) gout stones at particular sites, affecting function; (7) severely affecting appearance, preventing the wearing of clothes and shoes, etc.

## References

- [1] Marchini G S, Sarkissian C, Tian D, et al. Gout, Stone Composition and Urinary Stone Risk: A Matched Case Comparative Study [J]. *Journal of Urology*, 2013, 189(4): 1334–1339.
- [2] Towiwat P, Chhana A, Dalbeth N. The anatomical pathology of gout: a systematic literature review [J]. *BMC Musculoskeletal Disorders*, 2019, 20(1).
- [3] Dalbeth N, Gosling A L, Gaffo A, et al. Gout [J]. *The Lancet*, 2021, 397(10287): 1843–1855.
- [4] Ma L, Sun R, Jia Z, et al. Clinical characteristics associated with subcutaneous tophi formation in Chinese gout patients: a retrospective study [J]. *Clinical Rheumatology*, 2018, 37(5): 1359–1365.
- [5] Blandin C, Forien M, Gardette A, et al. Tophus size is associated with hallux valgus deformity in gout [J]. *European Journal of Clinical Investigation*, 2017, 48(1).
- [6] Briesacher B A, Andrade S E, Fouayzi H, et al. Comparison of Drug Adherence Rates Among Patients with Seven Different Medical Conditions[J]. *Pharmacotherapy: The Journal of Human Pharmacology and Drug Therapy*, 2008, 28(4): 437–443.