

Total elbow arthroplasty: report of 2 cases

Lei Huang^{1,3}, Rui Zhang², Liqiang Zhi³, Jianbin Ma^{1,3,*}

¹*Shaanxi University of Chinese Medicine, Xi'an, Shaanxi 712046, China*

²*Honghui Hospital, Xi'an Jiaotong University, Xi'an, Shaanxi 710054, China*

³*Department of Joint Surgery, Honghui Hospital, Xi'an Jiaotong University, Xi'an, Shaanxi 710054, China*

**Corresponding author*

Keywords: Total elbow arthroplasty, rheumatoid, trauma.

Abstract: Artificial elbow arthroplasty is to replace the damaged elbow joint due to trauma, rheumatoid and other reasons through artificial prosthesis. The authors collected 2 patients with traumatic and rheumatoid elbow arthritis who underwent elbow replacement and followed up for 2-5 years, which are reported as follows.

1. Introduction

A successful elbow arthroplasty can eliminate pain to the greatest extent, correct intra-articular and extra-articular deformity and restore the normal physiological activity of the elbow joint [1]. Due to the wide variety of postoperative complications, high incidence and there are great controversies in the indications of surgery, surgical approach and the choice of prosthesis [2], it develops slowly compared with other joint arthroplasty.

2. Traumatic arthritis

Case 1 was a 59-year-old male patient who developed progressive aggravation of right elbow pain and limitation of motion in 2008 and came to the clinic on August 6, 2015 due to increased right elbow pain caused by slipping and landing on the right hand. The results showed that the patient had clear consciousness, normal spirit, normal face, stable vital signs, enlarged deformity of right elbow joint, no local skin redness, obvious tenderness in medial and lateral space of right elbow joint, flexion range of motion of right elbow joint of 45 °-55 °, normal skin sensation of both upper limbs, normal radial pulse, good peripheral blood supply, and normal toe movement. X-ray (Figure 1A) showed severe degenerative changes in the right elbow joint, periarticular hyperosteoegeny, osteophyte formation, uneven articular surface, subchondral osteosclerosis of the distal humerus and ulna, and significant narrowing of the ulnar joint space. Osteoarthritis of the right elbow was diagnosed. All examinations met the indications for elbow replacement, and right total elbow arthroplasty was performed with a Coonrad-Morrey semi-constrained prosthesis under general anesthesia. The patient was placed in the supine position with the elbow on the surgeon's chest. Routine Aneuridian disinfection of the right elbow, draping, and pneumatic tourniquet were applied. A sigmoid incision was made in the posterior midline of the right elbow, about 16 cm in length, and the skin, subcutaneous tissue, and deep fascia were incised successively, the ulnar nerve was carefully freed and protected along the

ulnar nerve sulcus, a triceps tendon lingual flap was performed, the triceps brachii muscle was split longitudinally, osteophyte formation around the trochlea of the right humerus and around the olecranon was observed by dissection and exposure, osteophytes and medial and lateral collateral ligaments were cleaned, and the elbow joint was dislocated after biting part of the olecranon osteophyte, showing cartilage fissures and exfoliation on each bone surface of the elbow joint, humeral reaming was performed after further cleaning the intra-articular adhesions, humeral osteotomy was performed after placement of the humeral osteotomy guide plate, and a 6-inch humeral prosthesis trial was inserted Reaming was performed again after ulnar reaming, and insertion of a 3-inch ulnar prosthesis showed that the ulnar prosthesis trial was in good position with moderate tightness. The choice of prosthesis should not be greater. After the irrigation gun repeatedly irrigated the elbow joint, fix the 6-inch humeral prosthesis and 3-inch ulnar prosthesis with bone cement. The re-test of elbow joint showed moderate tightness, and the position of prosthesis was satisfactory. C-arm fluoroscopy showed satisfactory position of the prosthesis and good fixation. The occurrence of humeral condyle and olecranon fractures was prevented throughout the operation. The wound was repeatedly irrigated with normal saline, and a drainage tube was placed in the wound. After checking that the device dressing was correct, the soft tissue around the nerve was sutured for soft tissue bed protection of the ulnar nerve, and the wound was closed by suture layer by layer. Sterile dressing compression bandaging. Loosen the pneumatic tourniquet. Reexamination of X at 7 days after surgery (Figure 1B) revealed a flat articular surface, good position of the artificial elbow joint, no loosening or displacement, normal peripheral blood flow and skin sensation, and good wound healing. Elbow rotation 0°-65° before, 0°-60° after, 6° extension, 0°-125° flexion. The Mayo score was 93, and the patient was very satisfied with the postoperative results. X-ray and range of motion (Figure 1C) were well reviewed 5 years after surgery.

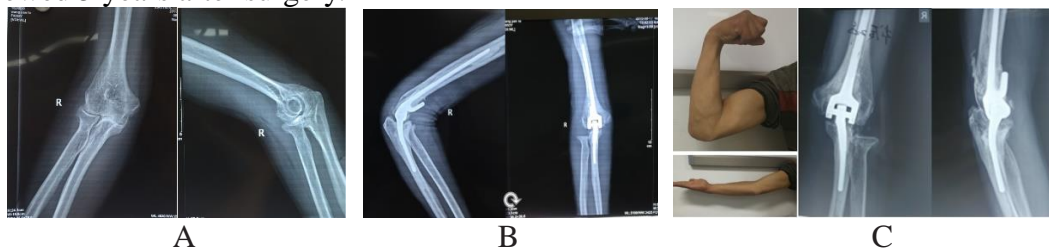


Figure 1: A: Anteroposterior and lateral X-ray of the affected elbow; B: Anteroposterior and lateral X-ray of the affected elbow 3 days after surgery, C: Range of motion and anteroposterior and lateral X-ray of the patient 2 years after surgery

3. Rheumatoid arthritis

Case 2 was a 50-year-old female patient who had pain and swelling of both elbows without obvious inducement in 2009, and gradually limited activities. Since 2014, the above symptoms were significantly aggravated, the pain was not significantly relieved after rest, and the pain also began to occur in both wrists. He was diagnosed with "rheumatoid arthritis" at another hospital. Because conservative treatment was not effective, surgical treatment was sought and he visited our hospital.(1) The patient had clear consciousness, fine spirit, normal face, stable vital signs, flexion deformity of both elbows, especially on the right side, no redness or swelling of local skin, significant tenderness in the medial and lateral spaces of both elbows, flexion range of motion of the left elbow joint: 10°-120°, flexion range of motion of the right elbow joint 90° ankylosis, extension ankylosis of the right wrist joint, and free movement of the left wrist joint. There was no deformity activity in both shoulders and between the joints. Skin sensation was normal in both upper limbs, radial pulses were normal, and peripheral blood supply was good. X-ray in our hospital (Figure 2A) showed stenosis of

the right brachial-ulnar and radio capitellar joint space, osteophyte hyperplasia, and uneven articular surface. Diagnosis of "rheumatoid arthritis" was confirmed by imaging and laboratory tests. The Coonrad-Morrey semi-constrained prosthesis was also used. The incision was about 10 cm. The ulnar joint was fused during the operation. The prosthesis selection was the smallest. The reexamination of X-ray 3 days after the operation (Figure 2B) showed that the articular surface was flat, the position of artificial elbow joint was good, without loosening or displacement, the peripheral blood flow and skin sensation were normal, and the wound healed well. Elbow rotation 0°-60° before, 0°-60° after, 5° extension, 0°-120° flexion. The Mayo score was 92, and the patient was very satisfied with the postoperative results. The range of motion (Figure 2C) was well reviewed 5 years after surgery.

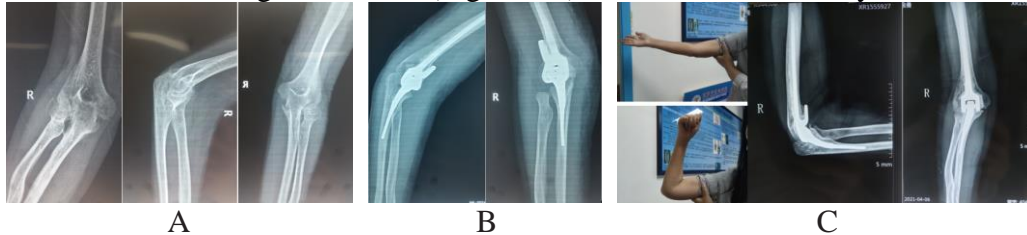


Figure 2: A: Anteroposterior view of the affected elbow; B: Anteroposterior and lateral view of the affected elbow 3 days after surgery; C: Range of motion and anteroposterior and lateral view of the patient 5 years after surgery

4. Discussion

The concept of "artificial elbow" has been proposed by Dee [3] in 1972, but the postoperative results are not satisfactory. Elbow complications have been reported to occur in up to 20% – 45% [4]. With the development of science and technology and the advancement of surgical techniques, the short-term follow-up outcomes of TEA have been greatly improved in recent years, and data from the Norwegian Arthroplasty Register from 1994 to 2016 showed 5-year, 10-year, 15-year, and 20-year survival rates for total elbow arthroplasty of 92%, 81%, 71%, and 61%, respectively [5]. In this paper, the triceps lingual flap approach was selected for all patients, and this approach can increase the range of elbow flexion, especially for those with triceps contracture, but also maintain the continuity of the medial head of the triceps and cubital muscles and preserve the blood vessels and nerves innervating the cubital muscles [6]. All patients had no obvious ulnar nerve symptoms, so the ulnar nerve was released in situ without selecting the anterior ulnar nerve, and the ulnar nerve was carefully freed and protected during the operation. The patient had no obvious ulnar nerve symptoms after the operation. The surgeon believed that this was greatly related to the treatment of ulnar nerve. Dachs [7] et al. performed upright release of ulnar nerve in 78 patients during total elbow arthroplasty. After operation, the symptoms of 2 patients subsided, 2 patients had obvious ulnar nerve symptoms requiring anterior ulnar nerve. The incidence rate of ulnar nerve symptoms was 5% (78 cases, 4 cases). Dachs' findings suggest that in situ release of the ulnar nerve reduces the risk of injury to the ulnar nerve during advancement. In terms of prosthesis selection, as with knee and hip arthroplasty, it follows that it is rather small than large. Radial head resection was also performed to increase elbow pronation and postrotation function. In this paper, rheumatoid patients had difficulty in flexion and extension and pain in the elbow joint that was originally on the healthy side 2 years after surgery, but the function of the elbow joint on the operated side recovered well and could assist in basic life movements such as combing and dressing. Prosthetic wear and aseptic loosening are the main causes of failure in elbow arthroplasty. In-Ho Jeon [8] and other studies have shown that elbow loosening is greatly related to the precoating of the ulnar component surface, while the selection of prosthesis with plasma coating attached to the ulnar side surface can significantly reduce the prosthesis loosening rate. Thanks to the progress of surgical techniques and the improvement of prosthesis research and

development, total elbow arthroplasty has become increasingly mature, and relevant domestic reports have also increased, of which there are many reports on elbow arthroplasty for complex distal humerus fractures, and the effect is also more significant. Xiaoxiao Chen [9] et al performed total elbow arthroplasty in 9 elderly patients with complex distal humerus fractures. The postoperative score was excellent and good rate of 78%. After operation, 1 patient had ulnar nerve inflammation and 1 had extensor weakness. The symptoms subsided after symptomatic treatment. Binyao Mao [10] also performed elbow arthroplasty in 14 patients with complex distal humerus fractures, except for 2 cases of mild pain during strong elbow extension after surgery, the rest had no pain. Some domestic scholars have also used 3D customized printed elbow prosthesis to treat comminuted distal humerus fractures, with significant short-term effect [11]. Haochen Tang [12] et al compared the clinical efficacy of open reduction and internal fixation with double locking plate and artificial total elbow arthroplasty in the treatment of complex distal humerus fractures in the elderly. The early clinical results showed that the Mayo score and excellent and good rate in the artificial elbow arthroplasty group were higher than those in the double locking plate internal fixation group. Elbow arthroplasty is also quite effective in the treatment of rheumatoid arthritis. Chunsheng Zhang [2] et al. performed arthroplasty in 11 patients with advanced rheumatoid arthritis. The Mayo score increased significantly before operation, 10 days after operation, 3 months after operation and during follow-up. The follow-up showed that the excellent and good rate was 100%. Malignant bone tumors around the elbow joint are also indications for elbow arthroplasty, but there are few relevant reports and existing reports show that there are many postoperative complications. Yong Li [13] et al. used specific limited prosthesis to treat 5 patients with bone tumors, and the pain was significantly relieved. However, 1 patient had ulnar nerve symptoms and 1 had prosthesis loosening planned for elective reoperation. Longfei Zou [14] reported that 7 patients with bone tumors had more postoperative complications, 1 had weakened triceps muscle strength, 2 had ulnar nerve symptoms, 1 had local tumor recurrence and amputation, and 2 died of multiple systemic tumor metastases after surgery. In summary, total elbow arthroplasty has achieved remarkable results in the treatment of complex distal humerus fractures and rheumatoid elbow arthritis, but due to the serious osteoporosis and bone defects in patients with malignant bone tumors around the elbow joint, the operation is difficult and the incidence of postoperative complications is also high, and more perfect technical options are needed to reduce the incidence of postoperative complications.

References

- [1] Xinjie Hong, Yunfei Niu. *Progress in Treatment of Artificial Elbow Replacement [J]. Chinese Journal of Shoulder and Elbow*, 2017, 5 (03): 226-30.
- [2] Chunsheng Zhang, Bin Du, Guangquan Sun, et al. *Analysis of Clinical Effect of Elbow Arthroplasty in the Treatment of Advanced Elbow Rheumatoid Arthritis [J]. Journal of Practical Orthopaedics*, 2019, 25 (11): 965-8 + 85.
- [3] DEE R. *Total replacement arthroplasty of the elbow for rheumatoid arthritis [J]. J Bone Joint Surg Br*, 1972, 54 (1): 88-95.
- [4] VOLOSHIN I, SCHIPPERT D W, KAKAR S, et al. *Complications of total elbow replacement: a systematic review [J]. J Shoulder Elbow Surg*, 2011, 20 (1): 158-68.
- [5] ZHANG D, CHEN N. *Total Elbow Arthroplasty [J]. J Hand Surg Am*, 2019, 44 (6): 487-95.
- [6] Chen Cheng, Xieyuan Jiang, Maoqi Gong. *Selection and Present Situation of Surgical Approach for Total Elbow Replacement [J]. China Journal of Orthopaedics and Traumatology*, 2014, 27 (01): 79-84.
- [7] DACHS R P, VRETTOS B C, CHIVERS D A, et al. *After Ulnar Nerve In Situ Release During Total Elbow Arthroplasty [J]. J Hand Surg Am*, 2015, 40 (9): 1832-7.
- [8] JEON I H, MORREY B F, SANCHEZ-SOTELO J. *Ulnar component surface finish affecting the outcome of primary Coonrad-Morrey total elbow arthroplasty [J]. J Shoulder Elbow Surg*, 2012, 21 (9): 1229-35.
- [9] Xiaokang Chen, Zhengjie Wu, Bingxue Zhou, et al. *Semi-restricted total elbow arthroplasty for the treatment of complex distal humerus fractures in the elderly: 1-year follow-up [J]. Journal of Clinical Rehabilitative Tissue Engineering Research*, 2019, 23 (08): 1167-71.
- [10] Binyao Mao, Xinchun Li, Mao Wang, et al. *Artificial Elbow Replacement for Old Complicated Distal Humerus*

Fractures [J]. Orthopedic Journal of China, 2012, 20 (08): 677-80.

[11] Naichao Wu, Qing Han, Shan Li, et al. 3D printing technology assisted preoperative design and reconstruction of elbow anatomy: a case report and literature review [J]. Journal of Jilin University(Medicine Edition), 2019, 45 (06): 1422-6 + 84-85.

[12] Haochen Tang, Ming Xiang, Hongxia Xu, et al. Comparison of the early effects of two surgical methods in the treatment of osteoporotic complex distal humerus fractures in the elderly [J]. Chinese Journal of Traditional Medical Traumatology & Orthopedics, 2016, 24 (08): 11-5.

[13] Yong Li, Baocang Wang, Shanshan Ma, et al. Treatment of malignant bone tumor around elbow joint with special constrained prosthesis replacement [J]. Journal of Practical Orthopaedics, 2021, 27 (09): 836-9.

[14] Longfei Zou, Jiang Guo, Hao Xue, et al. Treatment of malignant tumor bone destruction around elbow joint with custom-made restrictive prosthesis [J]. Orthopaedics Journal, 2020, 11 (06): 506-12.